
Detection of Glaucoma from Retinal Fundus Images by analysing ISNT Measurement and features of Optic Cup and Blood Vessels

Kartik Thakkar

BCA Department,
Vivekanand College,
Surat, India

Dr. Kinjan Chauhan

Dept. of Computer
Science,
Shree Ramkrishna
Institute of Computer
education & Applied
Science,
Surat, India

Dr. Anand Sudhalkar

M.S. Ophthalmologist,
Medical Research
Foundation
Sudhalkar Eye Hospital
and Retina Centre,
Vadodara, India

Dr. Ravi Gulati

Dept. of Computer Science,
Veer Narmad South Gujarat
University
Surat, India

ABSTRACT

Glaucoma is an ocular syndrome caused due to increased fluid pressure called Intraocular Pressure (IOP) in the optic nerve. It blocks the transmission of visual information to the brain which results partial or total vision loss. Glaucoma is one of the 2nd most leading causes of blindness. Glaucoma can be characterized by changes in Optic Nerve Head (ONH) structure & Retinal Nerve Fibre Layer (RNFL). Optic Nerve Head can be analysed for its Cup Shape, Notching and Cup to Disc Ratio to detect symptoms of glaucoma. RNFL is the first to be affected by Glaucoma disease. RNFL thickness can be found from Optical Coherence Tomography (OCT) test but it is still not widely used due to high cost and less availability. Another approach is to analyse Optic Nerve Head atrophy from images taken by normal Ophthalmoscope (Fundus Camera) to extract features of ONH and analyse morphological changes which are significant signs of glaucoma. Inferior Superior Nasal Temporal (ISNT) measures can be calculated by extracting circular edges of Optic Cup and Optic Disc as one of the important features of ONH. In this paper, we have proposed new algorithm to extract Optic disc and Optic Cup from fundus images which is used to analyse changes in ONH. This will help in classifying the image into Healthy or Glaucomatous.

KEYWORDS

GLAUCOMA, IMAGE PROCESSING, ONH, NOTCHING, CDR, OPTIC DISC, OPTIC CUP, ISNT.

1. INTRODUCTION

Glaucoma is one of the leading cause of blindness most possibly detected during the age from 40 to 80. Even though glaucoma detection techniques are there, it is estimated that by the year 2020, 76 million people are likely to get affected by glaucoma. The prevalence of glaucoma is 2.5% for people of all ages and 4.8% for above 75 years of age [1]. Glaucoma is an ocular disorder caused due to increased IOP (Intraocular Pressure) [2]. Diagnosis of glaucoma is mainly based on the IOP, medical history of patient's family, and change in optic disc structure [3]. Glaucoma suspect will have IOP more than 21 mmHg. Other methods of monitoring glaucoma involve Optic Nerve Hypoplasia Stereo Photographs (ONHSPs), advanced imaging technology such as OCT, Scanning Laser Polarimetry (SLP), and Confocal Scanning Laser Ophthalmoscopy (CSLO) to generate reference images to study the eye and its internal structure [3]. These methods are expensive and required skilled supervision. Combining various imaging methods will improve the accuracy of glaucoma identification. Fundus images can be analysed for morphological changes to detect whether eye is glaucomatous or Healthy. Texture pattern of image and ONH shape changes can be clearly analysed in retinal fundus images [Fig. 1-(a), Fig. 1-(b)]. Glaucoma can be characterized by structural changes in Optic Nerve Head due to the blockage to the discharge of aqueous humour, which results in increase IOP. This damages

optic nerve fibre layer and stops the transmission of information from eye to brain which affect patient's vision and results in partial or complete vision loss [4].

Optic Nerve area is in the interior of the eye. It is an entry and exit of nerve fibres. The shape of ONH varies from circle to elliptical. When nerve fibre reaches ONH, they take a turn and exit through the optic nerve which creates a small circular gap called cup as shown in figure 3. General purpose algorithms often fail to detect Optic Cup edges because of fuzzy boundaries[5].

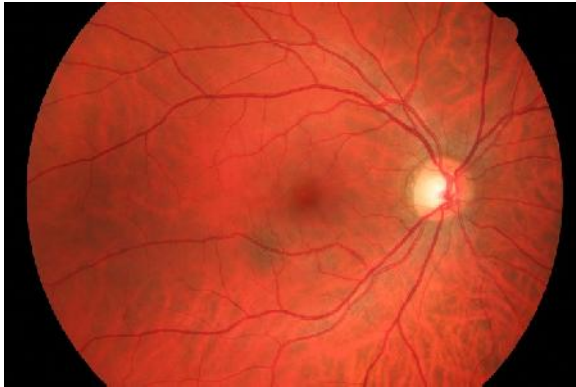


Fig. 1 (a) – Glaucomatous Retinal Fundus Image

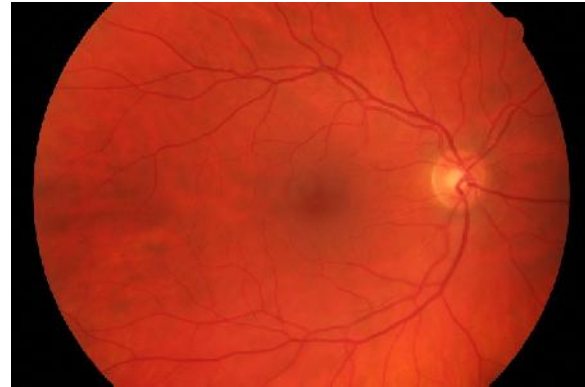


Fig. 1 (b) – Healthy Retinal Fundus Image

The size of cup and disc can be one of the parameters to diagnose glaucoma. ISNT Rules are used to differentiate between Glaucomatous and healthy eye since inferior distance between Optic Disc and Cup is always higher than Superior area and Nasal distance is always higher than Temporal distance in ONH in normal eye as shown in Fig. 2. If the distance between Optic Cup and Optic Disc does not obey this rule then the image can be suspected as glaucomatous. In fundus images shape of ONH may vary. Other parameters that can be used is intensity of cup since cup with glaucoma always has brightest intensity value. Notching can also be an important feature to detect glaucoma, and it can be detected from the shape of Optic Cup since the shape of Cup is abnormal (not circular) either at inferior or superior side in a glaucomatous eye. All these features can be analysed together to classify whether the eye is glaucomatous or not. This paper is divided into 3 sections. In the 1st section we have reviewed some quality research work in detecting and segmentation of ONH Regions and its features. In the 2nd section we propose an algorithm that combines different techniques of image processing and classification and in the 3rd section experimental results and their details have been noted with future scopes.

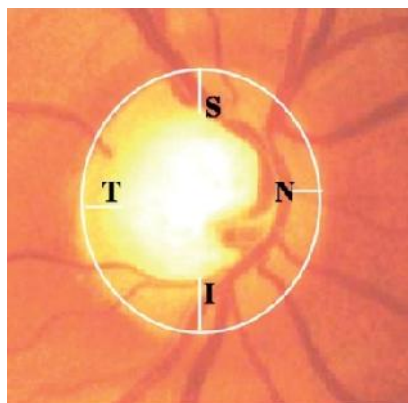


Fig. 2 : ONH Region with ISNT

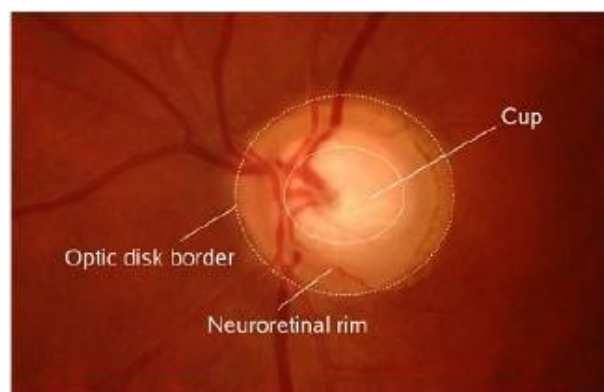


Fig. 3 : Retinal Image indicating edges of Cup and Disc

2. LITERATURE SURVEY:

In 2015, Muhammad et al. [4] proposed an approach to automatically classify normal and glaucomatous images based on Regional Wavelet Feature of the ONH & regions around it. Algorithm automatically determines clinically observed regions around the ONH and performs classification based on Wavelet Energy at different frequency sub bands. Experiments were conducted on RIMONE database with 158 images and classification accuracy was noted 93%. The author(s) took only one feature to classify images which is not sufficient. More features could have been used for concrete result.

In 2004, James Lowell et al.[5] proposed an algorithm for automatic localization and segmentation of ONH using deformable contour model and global elliptical model. The algorithm is evaluated on 100 random low resolution retinal images. The contour estimation algorithm was assessed and had excellent performance in 83% of cases, and performed well even on blurred images but Optic Cup and Optic Disc segmented using this algorithm did not have exact edges which may lead to wrong conclusion.

In 2006, Juan Xu et al.[6] modified previously used deformable model to extract features of Optic Disc for glaucoma analysis. In this paper, original deformable technique was used in two aspects: Knowledge-based clustering and smoothing. Contour deforms location into two groups: edge point group and uncertain point group which finally update the combination of local and global information. Algorithm was tested on 100 images and achieved 94% accuracy in locating cup and disc boundaries and features were used to find out cup to disc ratio for which success rate of classification was not mentioned and results were analysed under clinical validation but algorithm mainly focuses on only Cup and Disc boundaries and only one feature of CDR was detected for glaucoma analysis. And only one feature (CDR) is not sufficient to diagnose glaucoma. Other features should be added.

In 2014, Kittipol Wisaeng et al.[7] proposed an algorithm to detect Optic disc automatically. Algorithm uses Otsu method after implementing some morphological operations like colour normalization, contrast enhancement and noise removal. Algorithm was tested on STARE database and got success rate of 91.31% in locating optic disc but algorithm works only to locate Optic Disc, no edge detection or measurement was calculated between cup and disc.

In 2010, Arturo Aquino – Martin et al.[8] proposed template based methodology for segmenting Optic Disc. In this paper, morphological operation & edge detection techniques were used followed by Circular Hough Transformation. They also proposed voting type algorithm used to detect optic disc as a feature. This algorithm was evaluated on 1200 images on publicly available MESSIDOR database. Location of Optic Disc was detected in 99% cases and segmentation produced 86% result but only disc edge detection was not enough, cup edges also need to be segmented to diagnose glaucoma.

In 2012, Rashid Jalal et al.[9] proposed an efficient combination of algorithms for automated localization of Optic Disc. This paper works on the idea of implementing more than one algorithm to detect Optic Disc that gives more accuracy. Paper uses pyramidal decomposition, edge detection, entropy filter and Hough Transformation algorithms. Images from 3 different databases viz. Diaretdb0, Diaretdb1 and DRIVE were used but only to detect Optic Disc and macula which is not sufficient.

In 2014, Eleesa Jacob et al.[10] proposed super Pixel Classification method for glaucoma screening. Images were divided into Super Pixel with the use of simple iterative clustering algorithm. Optic Disc and Cup were detected from publicly available database using cup boundaries but result and dataset were not specified.

Other researchers have also worked in this area such as Blood vessel Segmentation using feature extraction techniques by Archana Sharma et al. in 2013[11] and using Unsupervised Texture Classification by Alauddin Bhuiyan in 2007[12], Anushikha Singh et al. in 2016[13] proposed Optic Disc segmentation and wavelet features and in the same year Sanjivani Shantaiya et al.[14] proposed a novel technique for ISNT and Neuro Retinal Rim. Srinivasan Aruchamy et al. [15] proposed Fractal techniques in the year 2015 and in the same year Mr. Prasad N. Maldhure used super pixel classification and histogram equalization and Gabor filtering for optic disc segmentation [16]. In 2014, M.Lakshmi et al. proposed Multi thresholding Method with Median Filter to detect Glaucoma[17]. Some other Techniques are listed in the following Table 1.

Table 1: Techniques used for Glaucoma Detection using Features of ONH and its surroundings.

Year and Authors	Techniques	Features
2014, José Abel de la Fuente-Arriaga et al.[18]	Vascular bundle displacement	Blood Vessels and Optic Cup
2014, Adithya Kusuma Whardana et al. [19]	K-Means Clustering Method	Optic Disc
2013, Fatma A. Hashim et al. [20]	Gaussian Filter and Intensity Extraction	Optic Disc
2013, Mei Hui Tan et al. [21]	Segmentation and Feature Point Selection	Notching in Optic Cup
2013, Deepali A. Godse et.al. [22]	Region Thresholding	Optic Disc and Blood Vessels

3. PROPOSED METHODOLOGY

As can be seen from the literature review, the researchers independently focused on detecting or segmenting Optic Cup and Optic Disc with success rate of more than 70% on an average but only segmented Optic Cup and Optic Disc are not enough to identify whether the patient is glaucomatous or not. Our proposed research takes 4 different features of ONH that can be used to specify the glaucomatous effect. These features are then combined in one main algorithm that classifies the image in 3 groups as Glaucomatous, Healthy and unresolved. Following diagram shows block representation of proposed model containing 3 phases; in the 1st phase we have done pre-processing of the images viz. Cropping, Resizing, Transformation, Dilation. In the 2nd phase we have done segmentation of Optic Cup, Optic Disc & Blood Vessels, Thresholding & Analysis of Intersection between Cup and Blood Vessels and Shape of the Cup and finally in the 3rd phase we did classification using result obtained from the 2nd phase.

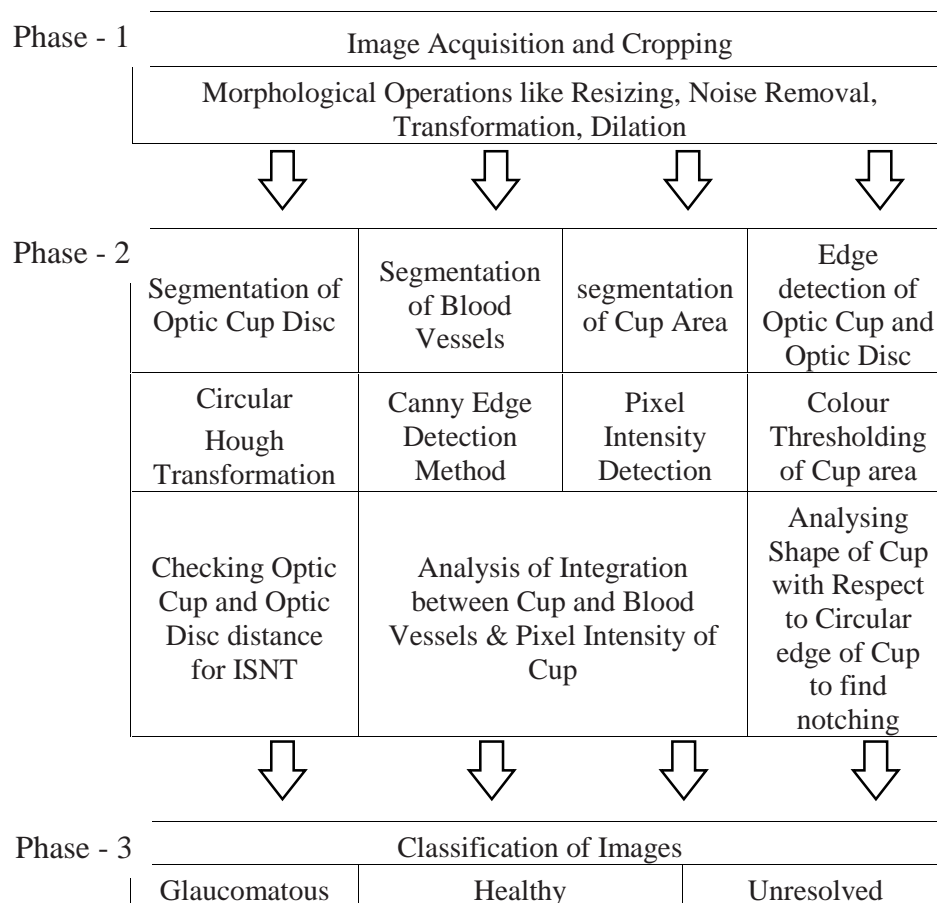


Fig. 4: Block Diagram of Proposed Methodology

Pre-processing of image includes resizing the image into fixed 500px X 768px size, cropping the image to get only Retinal area and Noise removing to clear the Region of Interest. After pre-processing we located centre pixel of Optic Cup by using Pixel Intensity, after that we cropped image again to position Optic Disc at centre of the image. Hough Transformation techniques was applied to get circular edges of Optic Cup and Optic Disc as shown in Fig.5(a). ISNT Values were calculated using distance between Optic Cup and Optic Disc as shown in Fig.5(b) and result was calculated to classify whether Image obeys the rule of ISNT or not.

After getting ISNT result, we have applied blood vessel segmentation using Canny Edge detection method to get edges of blood vessels as shown in Fig.5(c) inside Optic Disc area and compared the edges with cup area found in previous step, to check whether blood vessels are intersected with the area of cup or not. Result of Intersection were used in classification.

We also used colour thresholding using manual parameters to get clear edges of Cup area from Blue Channel of the image as shown in Fig.5(d). Edges were plotted on circular cup edges to find notching of cup area in inferior or superior side. And we have also checked the intensity values of cup area to make sure they were whiter than the disc if other result shows that image was glaucomatous.

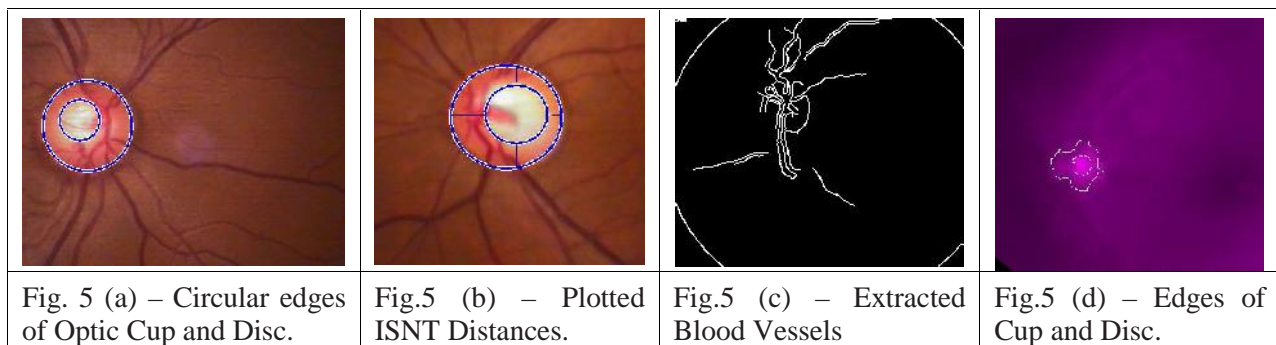


Fig. 5: Result images of Algorithm steps

Our proposed work includes:

- i) Techniques to locate Optic Disc using Pixel Intensity Detection
- ii) Separating Optic Cup and disc boundaries using Circular Hough Transformation
- iii) Segmentation of Optic Cup and Optic Disc using Colour Thresholding using variable values for each image
- iv) Segmentation of blood vessels using Canny Edge Detection Method
- v) Analysis of Cup and Vessel intersection and
- vi) Analysis of intensity of cup as a feature.
- vii) Classification of the fundus image into Glaucomatous or healthy.

All these processes are combined into one GUI tool. We have used Matlab to make GUI tool that provides manual parameter tuning for thresholding value of colour images. And calculate result of all 3 phases of the algorithm. And if any of the 3 features out of 4 show positive sign of glaucoma then we consider the image to be glaucomatous.

4. EXPERIMENT AND ANALYSIS

Algorithms were tested on 150 Private Dataset taken from Eye Hospital, Vadodara, and 40 public STARE Database. In the 1st phase we got fixed size cropped image without any noise so that desired feature like blood vessels and ONH can be clearly visible as shown in Fig. 6(a).

In the 2nd phase the Optic Cup and Optic Disc were segmented with circular boundaries as shown in Fig. 6(b). ISNT values were calculated using edges of Cup and Disc to check whether they obey ISNT Rules as shown

in Fig. 6(c). Blood vessels were extracted using edge detection technique from normal image as shown in Fig. 6(d). Cup edges were segmented using manual thresholding value that gave exact area between Cup and Disc called rim area as shown in Fig. 6(e). Circular Cup area was compared with Cup edges segmented from thresholding and notching was detected. Other features like intersection of Blood Vessels with Cup area and Intensity value of cup were also successfully extracted and results were used in the 3rd phase.

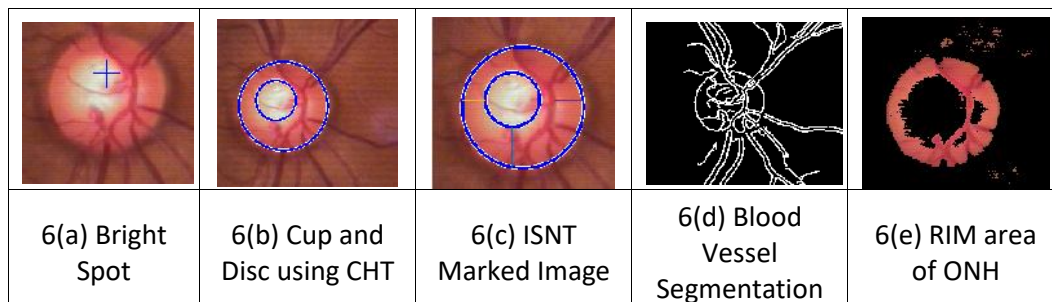


Fig. 6: Result images of algorithm

In the 3rd phase the images are classified as Glaucomatous, Healthy and Unresolved based on the results given by all 4 steps of the algorithm.

4. CONCLUSION

By analysing various methods used by different researchers for Glaucoma detection we can conclude that Glaucoma has structural changes on ONH and its features. These structural changes can be analysed using morphological operations and some other image processing techniques. Our Algorithm uses four different features of ONH used to detect glaucoma. This algorithm works effectively because it uses four features of ONH together and uses the results in grouping the image into Glaucomatous, Healthy or Unresolved. Further research can be done by analysing textural changes of RNFL. RNFL bundle loss can be detected in consecutive images by using image processing techniques; this parameter can be analysed on retinal fundus images which results in detecting glaucoma in its very early stage.

5. REFERENCES

- [1] Hemma Resch, Ivania Pereira and Clemens Vass, "Retinal Blood Vessel Distribution Correlates With the Peripapillary Retinal Nerve Fiber Layer Thickness Profile as Measured With GDx VCC and ECC," *Journal of Glaucoma*, vol. 00, no. 00, pp. 1-7, Feb 2015.
- [2] P. N. Schacknow and J. R. Samples, Eds., *The Glaucoma Book A Practical, Evidence-Based Approach to Patient Care*, Springer.
- [3] Shishir Maheshwari, Ram Bilas Pachori and U Rajendra Acharya, "Automated Diagnosis of Glaucoma Using Empirical Wavelet Transform and Correntropy Features Extracted from Fundus Images," *IEEE Journal of Biomedical and Health Informatics*, pp. 1-11, March 2016.
- [4] Muhammad Salman Haleem, Liangxiu Han, Jano van Hemert and Alan Fleming, "Glaucoma Classification using Regional Wavelet Features of the ONH and its Surroundings," *IEEE Journal of Biomedical*, pp. 4318-4321, 2015.
- [5] A. H. James Lowell, "Optic Nerve Head Segmentation," *IEEE TRANSACTIONS ON MEDICAL IMAGING*, vol. 23, no. 2, pp. 0278-0062, 2004.
- [6] J. J. S. L. Mira Park, "Locating the Optic Disc in a Retinal Image," 2006.
- [7] Kittipol Wisaeng, "Automatic Detection of Optic Disc in Digital Retinal Images," *International Journal of Computer Applications*, vol. 90, no. 5, pp. 0975 - 8887, 2014.
- [8] R. M. Rangayyan, "Detection of the Optic Nerve Head in Fundus Images of the Retina with Gabor Filters and Phase

- Portrait Analysis,” *Journal of Digital Imaging*, vol. 23, no. 4, pp. 438 - 453, 2010.
- [9] L. K. Rashid Jalal Qureshi, “Combining algorithms for automatic detection of optic disc and macula in fundus images,” *Computer Vision and Image Understanding*, vol. 116, pp. 138-145, 2012.
- [10] R. Eleesa Jacob, “A Method of Segmentation For Glaucoma Screening Using Superpixel Classification,” *International Journal of Innovative Research in Computer and Communication Engineering*, vol. 2, no. 1, pp. 2536 - 2543, 2014.
- [11] H. Archana Sharma, “Detection of Blood Vessels and Diseases in Human Retinal Images,” *International Journal of Computer Science and Communication Engineering*, pp. 9 - 11, 2013.
- [12] B. N. Alauddin Bhuiyan, “BLOOD VESSEL SEGMENTATION FROM COLOR RETINAL IMAGES USING UNSUPERVISED TEXTURE CLASSIFICATION,” 2007.
- [13] M. K. D. M. P. Anushikha Singha, “Image processing based automatic diagnosis of glaucoma using wavelet features of segmented optic disc from fundus image,” *computer methods and programs in biomedicine*, vol. 24, pp. 8-20, 2016.
- [14] S. G. Sanjivani Shantaiya, “Early Detection of Glaucoma Using Retinal Fundus Images,” *Imperial Journal of Interdisciplinary Research (IJIR)*, vol. 2, no. 6, 2016.
- [15] P. B. G. S. Srinivasan Aruchamy, “Online Optic Disk Segmentation Using Fractals,” *International Journal of Medical, Health, Biomedical, Bioengineering and Pharmaceutical Engineering*, vol. 9, no. 3, 2015.
- [16] P. V. V. D. Mr. Prasad N. Maldhure, “Glaucoma Detection Using Optic Cup and Optic Disc Segmentation,” *International Journal of Engineering Trends and Technology (IJETT)*, vol. 20, no. 2, 2015.
- [17] M. B. M. Lakshmi, “Glaucoma Detection from Color Fundus Images Using Multithresholding Method with Median Filter,” *International Journal of Inovative Research and Development*, vol. 3, no. 9, 2014.
- [18] J. Abelde laFuente-Arriaga and Edgardo M. Felipe-Riverón, “Application of vascular bundled is placement in the optic disc for glaucoma detection using fundus images,” *Computers in Biology and Medicine*, vol. 47, pp. 27-35, 2014.
- [19] A. K. Whardana and N. Suciati, “A Simple Method for Optic Disk Segmentation from Retinal Fundus Image from Retinal Fundus Image,” *I.J. Image, Graphics and Signal Processing*, vol. 11, pp. 36-42, 2014.
- [20] N. M. S. Fatma A. Hashim, “Automatic Segmentation of Optic Disc from Color Fundus Images,” *jokull Journal*, vol. 63, no. 10, pp. 143-153, 2013.
- [21] Y. S. Mei Hui Tan, “AUTOMATIC NOTCH DETECTION IN RETINAL IMAGES,” *IEEE 10th International Symposium on Biomedical Imaging*, pp. 7-11, 2013.
- [22] D. A. Godse and D. D. S. Bormane, “Automated Localization of Optic Disc in Retinal Images,” *IJACSA International Journal of Advanced Computer Science and Applications*, vol. 4, no. 2, 2013.
- [23] *. O. C. Juan Xua, “Optic disk feature extraction via modified deformable model technique for glaucoma analysis,” *Pattern Recognition*, vol. 40, pp. 2063-2076, 2007.
- [24] S. Jayanthi Sivaswamy, “A Comprehensive Retinal Image Dataset for the Assessment of Glaucoma from the Optic Nerve Head Analysis,” *JSM BIOMEDICAL IMAGING DATA PAPERS*, 2015.
- [25] M. Noga Harizman and M. Cristiano Oliveira, “The ISNT Rule and Differentiation of Normal From Glaucomatous Eyes,” *ARCH OPHTHALMOL*, vol. 124, pp. 1579 - 1584, 2006.
- [26] G. C. G. Jost Bruno Jonas, “Optic Disc, Cup and Neurorefinal Rim Size, Configuration ond Correlations in Normal Eyes,” *Investigative Ophthalmology & Visual Science*, vol. 29, no. 7, 1988.
- [27] A. Bhuiyan, B. Nath and J. J. Chua, “Blood Vessel Segmentation from Color Retinal Images using Unsupervised Texture Classification.,” *Research Gate*, 2007.
- [28] M. E. G.-A. a. D. M. Arturo Aquino*, “Detecting the Optic Disc Boundary in Digital Fundus Images Using Morphological, Edge Detection, and Feature Extraction Techniques,” *IEEE TRANSACTIONS ON MEDICAL IMAGING*, 2010.
- [29] K. Chauhan, P. Chauhan, A. Sudhalkar and R. Gulati, “Data Mining Techniques for Diagnostic Support of Glaucoma using Stratus OCT and Perimetric Data,” *International Journal of Computer Applications*, vol. 151, no. 8, 2016.